



# Prosthesis for blepharoptosis and blepharospasm

HERBERT L. MOSS, O.D.

**ABSTRACT**—*Blepharoptosis and blepharospasm are ocular phenomena, which cause severe functional and cosmetic problems. Both conditions respond poorly to medical and surgical correction, although surgery does provide a moderate degree of success in ptosis cases. Ptosis prostheses (crutches) have been utilized for years with only limited degrees of success. It is the author's opinion that this has been due to a lack of scientific approach to the design and limitations of the materials available for the device. To eliminate these problems, we devised and organized an approach to the design of the prosthetic device and utilized new materials with advantageous characteristics for the crutch. The results have been remarkable from a cosmetic and functional aspect and have produced an improvement in a condition considered beyond the pale of relief or treatment.*

**KEY WORDS** — *blepharoptosis, blepharospasm, ptosis prosthesis (crutch).*

## Introduction

Blepharoptosis and blepharospasm are two ocular problems that have resisted satisfactory cures or treatment. Ptosis surgery at best, leaves much to be desired and blepharospasm is much less responsive to surgical intervention. Ptosis prosthetic devices, in the form of scleral contact lenses, have had limited success and most of the attachments to spectacle frames have done very little better. The one device designed by Dr. J. C. Neill has afforded the greatest degree of success<sup>1</sup> and the author has based his design on this model.

The original concept in this pa-

per deals with four distinct innovations. Firstly, a new wire material and teflon tubing borrowed from the field of orthodontia. Secondly, a logical scientific method for placement and attachment of the appliance. Thirdly, the use of modern plastic spectacle frames to simplify the fabrication and improve the appearance. Finally, the use of tinted lenses to mask the crutch and improve the cosmetic effect.

These improvements permit normal elevation and full closure, allowing the lid to function in a normal manner and prevent drying of the cornea. The increased activity of the dormant neural and muscular systems has resulted in a functional improvement in one young congenital patient and in one older traumatic ptosis case. A good result was obtained in one blepharospasm patient with a possible multiple sclerosis etiology and a fair result was seen in a severe idiopathic blepharoptosis with heavy emotional overlay.

## Description of disease and treatment

Ptosis or blepharoptosis is a drooping of the upper lid with narrowing of the palpebral fissure, smoothing of the upper lid, and loss of the lid fold. It may be bilateral (color plate 1) or unilateral (color plate 2). All degrees of ptosis exist. When severe, it interferes with vision by covering the pupil. Patients attempt to raise the lid by forced action of the frontalis muscle by wrinkling the skin of the forehead

and raising the brow. When the condition is severe and bilateral, they favor exposure of the pupil by throwing the head backward. Their actions are characteristic accompaniments of this anomaly.<sup>2</sup>

Ptosis may be congenital or acquired. When congenital, it is usually bilateral and due to abnormalities of the oculomotor nerve. Acquired ptosis is usually unilateral. It may be due to neural, muscular, or mechanical factors.

Blepharospasm consists of repeated involuntary forceful closure of the lids which may be initiated by voluntary facial movements. Although the cause is frequently unknown, a significant number of patients with idiopathic blepharospasm will eventually show signs of Parkinson's disease. One of the two patients cited below had multiple sclerosis which could have been a contributing factor, but the second patient had no apparent generalized neurological involvement.

The choice of treatment depends upon the cause of the ptosis, the extent, and the associated lesions. If medical treatment fails or is contra-indicated, a surgical intervention may be required. However, the surgery is complicated and seldom produces complete correction of the defect. A general ophthalmologist summed up the surgical procedures that fail by citing three causes: insufficient lift, inadequate closure, and poor cosmetic results, in general. My personal experience, although all with surgical failures, or where surgery was contra-indicated or not desired, is that a ptosis

crutch should be considered and tried before surgical intervention. Admittedly, many present day ptosis crutches are doomed to failure. However, a properly designed crutch, as will be seen, becomes such a vital part of the wearer's existence that giving it up is the farthest thing from their mind.

### **Scleral lens ptosis correction**

One approach that has surfaced in the literature as a method of relieving ptosis, is the use of a scleral contact lens. These lenses may either be preformed, moulded, flush fit, or minimum clearance, as the circumstances indicate.

There are two methods of correcting a ptosis by use of scleral lenses. One is to build up the superior flange of the shell by increasing the mass. This will move the upper lid and improve the ptosis. However, it does make the upper lid more prominent and does not create a super-orbital fold. The second method is to place a shelf across the upper section of the scleral lens to support the upper lid. Obviously, when the lid is elevated to fit over the shelf, it becomes immobilized and blinking is not possible. While the eye is protected from drying off by the contact lens, which is an advantage, the lack of blinking makes for a very poor cosmetic result.

Having prescribed scleral lenses for all of my professional life and still one of their greatest advocates, I tried both of these methods. I am reluctant to report that all of my attempts have been eminently unsuccessful, but respect those who continue to use them with success.

### **Early ptosis crutch design**

An alternative approach, which has been used for many years, is the fitting of a ptosis crutch. Unfortunately, the ptosis crutches that are most common, are generally fixed crutches of plastic or metal, attached by one means or

another, to a spectacle frame, and frequently, the results leave much to be desired. The crutches utilizing 12% platinum alloy wire of 19 or 20 gauge thickness, soldered to a metal bridge, with the temporal end floating freely, and carefully formed to fit over the eye into the palpebral fold, are the most successful type. However, due to the difficulty in constructing and fitting, these have not been widely used.

This type of ptosis crutch was designed and described by Dr. John Neill, and prescribed for a patient in 1929, who was referred to the clinic of the Pennsylvania College of Optometry, by Dr. William Feinbloom of New York. The crutch was actually designed to alleviate a bilateral entropion which caused so much pain that the patient preferred keeping his eyes closed. The actual design was suggested by the patient's own discovery that applying an aluminum eye-cup to his eyes without solution, gave him considerable relief. This eventually led to the free-floating platinum crutch attached to the bridge of the spectacle frame.

In making this type of ptosis crutch, Dr. Neill made a facial impression and stone casts of the lid area and would then form the platinum wire into the superior palpebral fold, if one existed. As a student of Dr. Neill, I used this moulding method on several patients but found that the return was not worth the effort. With proper measurements and correct initial position of the fixed end of the crutch, the loose end could easily be bent by hand and pliers to fit. The wire could be made to fit the fold or create a fold and exert sufficient pressure to raise the lid and permit it to close upon blinking. Unfortunately, the thickness of the wire and inadequate flexibility did not permit full closure, even though it was a major improvement over all prior crutches. Other problems

were the use of metal frames which required soldering to the bridge, thus limiting the positioning of the fixed end of the crutch and once attached improperly, removal and resoldering were difficult.

While Dr. Neill must be credited with the major advance in this field, it was reported in the *Encyclopedia of Ophthalmology*<sup>3</sup> that ptosis crutches were first worked upon prior to 1890 and numerous others had suggested various devices of this nature.

### **New material and scientific design of prosthesis**

The purpose of this paper is to describe improvements over all existing crutches, by utilizing a new wire material and a logical scientific method of fixing the wire to the bridge of a modern frame to improve the overall cosmetic appearance and give greater movement to the upper lid. This new material is technically referred to as 304 stainless steel, 18-8 orthodontic round wire.<sup>a</sup> The exact ingredients are 18% chrome, 8% nickel, and 74% iron, and it is essential that it is spring tempered quality. It is important to stress that this is designed for orthodontic use and has a specially high polished finish, to reduce or prevent interaction with the mucous membrane of the mouth. This is a very desirable characteristic and since using this material, there have been no skin reactions at all. The wire is available in various thicknesses, but for ptosis crutches, the most appropriate are from 0.020 to 0.022 inches, depending upon the weight of the upper lid and the degree of lift required by the defect.

The patient shown in color plate 2, had a heavy scar from unsuccessful surgery and an anterior symblepharon which required a 0.026 gauge wire to get the proper lift. He had worn a crutch designed by Dr. Neill 25 years ago and wore

it very successfully. He did experience constant tearing with his original crutch and was very pleased to find that it disappeared with the new prosthesis.

In the two blepharospasm patients where this technique was used, a heavier gauge of 0.028 inches was used in one and a 0.032 in the second. The strength of the wire must be varied with the force of the blepharospasm and trial and error must be resorted to. The gauge of the wire should be heavy enough to raise the lid to a normal position, yet light enough to permit the lid to close upon blinking to prevent drying of the cornea. The principal advantage of this wire, over all previous materials used, is that it can be bent at a right angle without breaking and can be bent into tiny circles to form a spring action, if greater lift is needed. Thus, it can be bent to go through a plastic frame several times, to anchor it firmly and support the lid. The material does not respond to soldering, although silver solder can be used with considerable difficulty. It is well to avoid the use of metal frames for this reason. There are many types of orthodontic wire available in silver and gold finish and as long as they meet the required characteristics, they are suitable.

### Selection of frame

The best choice of frame (color plate 3) is a medium weight plastic with a saddle bridge that sits firmly on the bridge of the nose and has riding bow temples to prevent slippage, although conventional skull temples can also be used. A saddle bridge is advantageous because it provides greater stability.

### Attachment of prosthesis to frame

Figure 1 shows three holes of the same gauge as the wire, drilled into the bridge and eye-wire on the side

of the affected eye. The center hole only goes halfway into the plastic material from the back of the bridge. Depending upon the anatomy of the eyelids, either the bottom hole or the top hole should be at the level of the inner canthus. The holes are then connected by a channel cut into the surface of the frame, to permit the wire to be countersunk. The wire is then placed into the center hole and

bent at right angle, up and away from the hole which is level with the inner canthus. Then the wire is brought through the far hole and down along the channel of the front of the frame. From here, the wire is pulled through the third hole, permitting it to emerge level with the canthus on the affected side (Fig. 2).

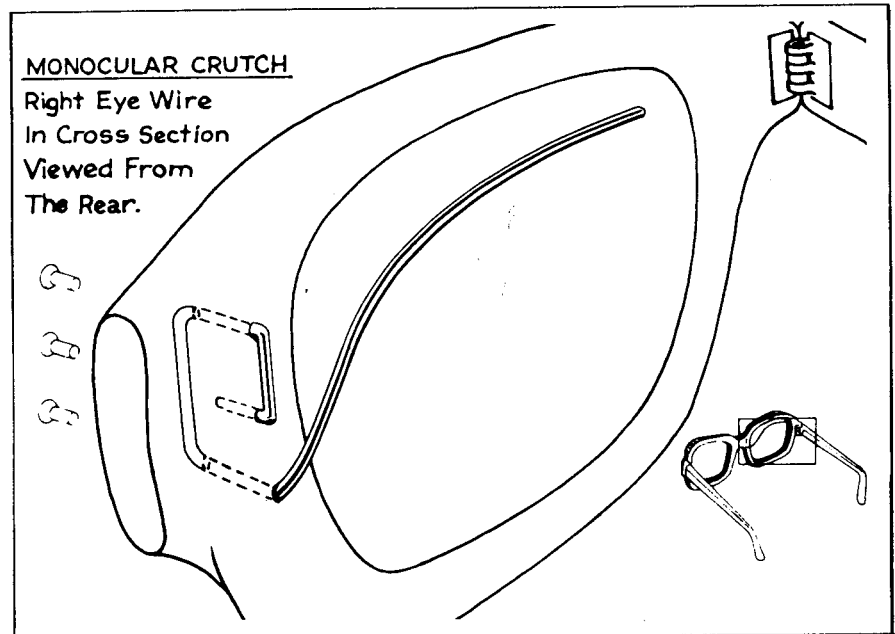
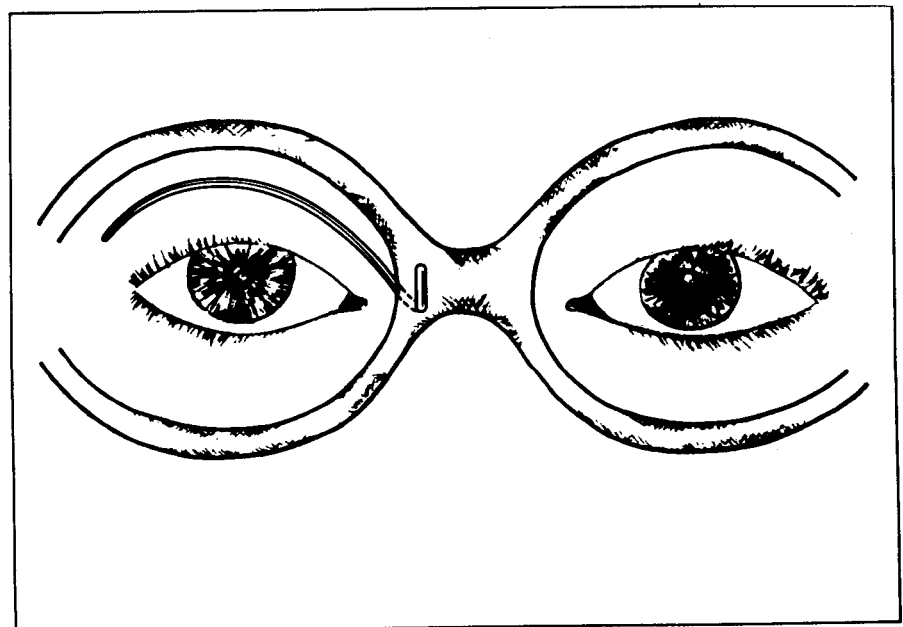


Figure 1: Cross section

Figure 2: Front view



### BINOCULAR CRUTCH Viewed from Above

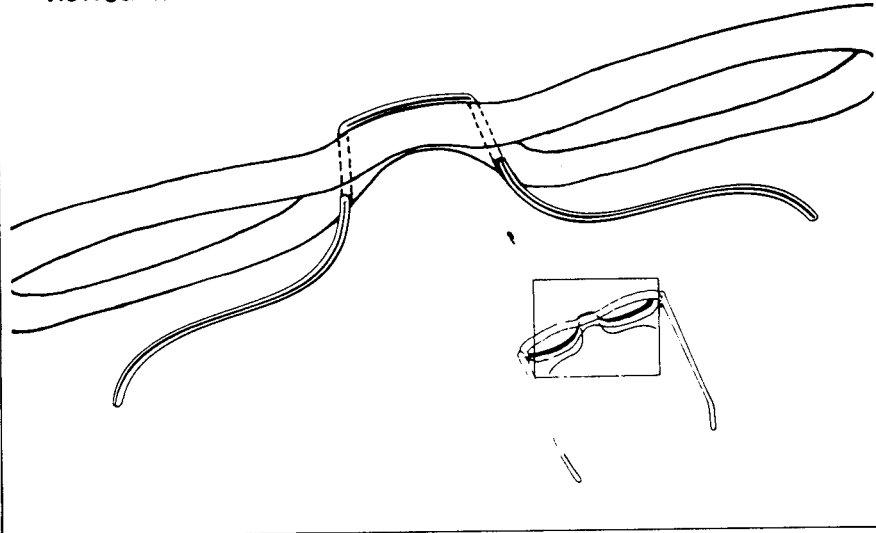


Figure 3: Ptosis (bilateral crutch)

In case of bilateral ptosis, only two holes may be required (Fig. 3). Where the canthi are below the center of the bridge, the wire going from hole to hole may be curved to form a saddle and avoid hitting the bridge of the nose. A small amount of cyanocrylate glue can be deposited at all drilling points and the crutch will be firmly fixed.

#### Forming the prosthesis

As the wire emerges at the level of the inner canthus, it is bent toward the eye in a slight upward direction, along the side of the nose, until it strikes the lid at the most nasal point of the upper palpebral fold, or where the fold should normally be. In monocular ptosis, if there is no fold, this point should be gauged by the opposite eye, in an effort to obtain symmetry. The wire can be bent by pliers or formed by hand, to fit into or create the palpebral fold, so that it gives a natural appearance and exerts the correct amount of lift. It is important to get the exact upward pressure necessary to permit the lid to close completely and prevent

drying of the cornea, which can have serious complications. This is strictly a matter of trial and error and can be time-consuming, but there is no simple way to predetermine the shape, position, and amount of pressure required. The wire is then cut at the temporal end, filed smooth and curved slightly outward to prevent digging into the tissue of the lid. The wire should not be cut too short or the appearance is compromised. A final decision on this should be delayed until the crutch is finally adjusted.

If skin irritation occurs or if the tip of the wire digs into the skin and cannot be relieved by bending alone, then teflon tubing should be used to cover the wire. Such tubing is available from orthodontic suppliers in two sizes. One will fit the wire of 0.020" to 0.022" diameter and the other will fit wire of 0.024" to 0.028" diameter.

The final adjustment is critical. It must have just enough pressure to elevate the lid, but not too much to prevent a full blink, nor create an ectropion of the upper lid. It cannot press on the globe and cause discomfort from pressure, nor

should it press the lid hard enough to interfere with the superficial blood supply and cause an erythema. Finally, the end of the wire should not be visible but should not dig into the lid and cause discomfort.

#### Case reports demonstrating results

Patient #1, is a 16-year-old girl whose congenital ptosis caused her considerable anguish from a cosmetic and functional aspect (color plate 4). Her upper lids are completely smooth, lacking a palpebral fold and her palpebral apertures are very narrow. The ptosis crutches (color plate 5) create a natural fold and are totally invisible from frontal view. The frame is contemporary, although not too large and the use of a 10% tint helps to hide the entire crutch. The beneficial emotional impact on this young lady is remarkable. From an introverted sixteen-year-old, she underwent a great personality change to become a bright, extroverted individual. One totally unexpected result was the patient's comment after three months of wear that she felt there was a marked improvement in her ability to elevate her lids when not using the prosthesis. Repeated photographs taken at this time, without her crutches, confirm her report (color plate 6).

I hesitated to report this result because of the high degree of improbability and questionable improvement of paralyzed muscles, until I found the following comment in the literature, as far back as 1954, and my concern was alleviated. Dr. Arthur E. Tillisch stated, "Apart from thus providing adequate support without irritation, there is supplementary and important purpose here: to provide a massaging effect on the lids when the eyes rotate to obtain fixation. This results not only in helping restore tonicity to muscles atrophied through disuse, but may also facil-

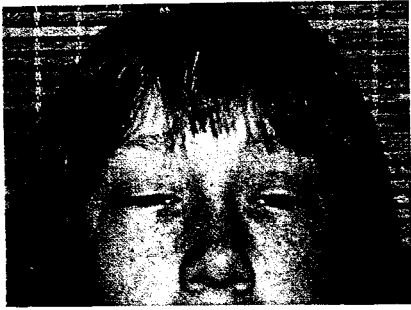

PLATE 1



PLATE 2




PLATE 3

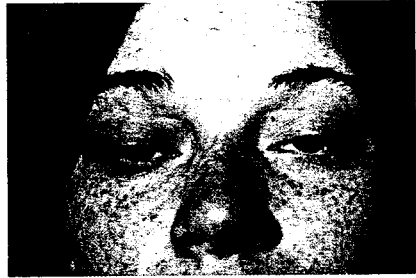

PLATE 4

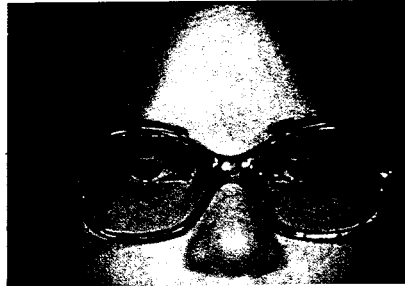

PLATE 5

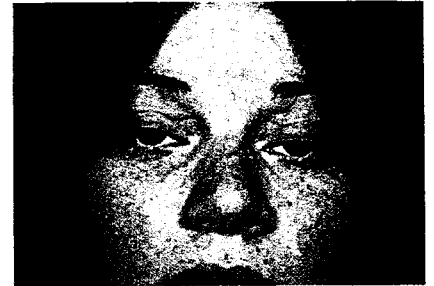

PLATE 6

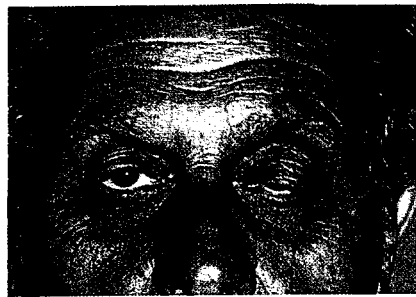

PLATE 7



PLATE 8

Plate 1—Bilateral ptosis  
Plate 2—Unilateral ptosis  
Plate 3—Ptoxis frames

Plate 4—Congenital ptosis, bilateral  
Plate 5—With crutch  
Plate 6—After wearing crutch

Plate 7—Ptosis, monocular  
Plate 8—Monocular ptosis corrected

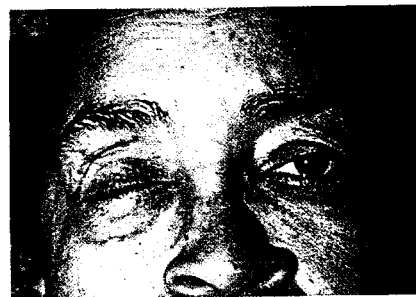

PLATE 9

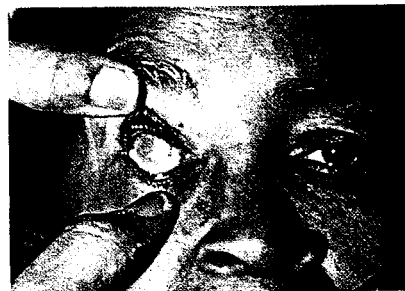

PLATE 10

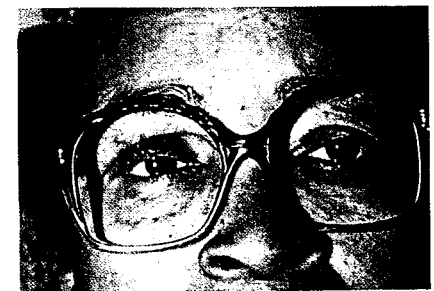

PLATE 11

Plate 9—Ptosis, monocular traumatic  
Plate 10—Ptosis, traumatized eye  
Plate 11—Ptosis corrected

Plate 12—Blepharospasm  
Plate 13—Blepharospasm with crutch

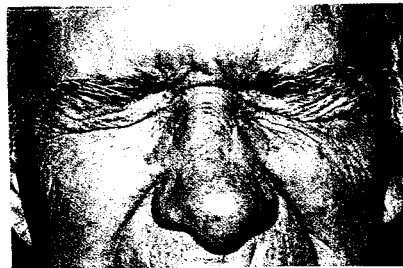

PLATE 12



PLATE 13



itate dormant neural functioning. I am aware that this latter aspect may be questioned, but I believe adequate literature exists to substantiate the hypothesis that neural growth and possible rejuvenation may be a function of such activities as mechanical stimulation."<sup>4</sup> This aspect of ptosis crutches opens intriguing possibilities and should be given very serious consideration before embarking upon a delicate, difficult, and frequently unrewarding surgical intervention.

Patient #2 (color plate 7) is a college professor, age 58, who has a congenital monocular ptosis. This has been a serious problem from several aspects. First, in order to mask the ptosis, he would walk around with his head tilted back, causing him to look down his nose, giving an impression of being snobbish and drawing comments from his colleagues and students. In addition, he was monocular, had a restriction of his left field of vision and was under considerable stress due to the wrinkling of his brow and forced action of the frontalis muscle. He had contemplated surgery on several occasions, but could never quite make the decision because of the questionable results.

For this patient, we prescribed a monocular crutch (color plate 8) and after two months of wear, the patient reported the following: firstly, his colleagues and students were surprised by his change of head posture, but never became aware of the cause of his so called "cure." Secondly, he reported great pleasure upon having binocular vision and a complete field of view. Finally, and most surprisingly, he stated that he felt much less stress, less nervousness, and a feeling of general improvement in his emotional stability.

It is somewhat difficult to reconcile such far-reaching impact from a simple ptosis crutch, but his comments were strictly voluntary,

with no effort to solicit them, either by me or the interns assisting on this case.

Patient #3, female, age 50, presented a monocular ptosis and a severely damaged eye on the same side, due to a fall down a flight of stairs. Color plate 9 shows the ptosis and color plate 10, with the eye held open, reveals the ocular result of the trauma. The eye showed a glossy white appearance from fibrous retinal tissue and traumatic aniridia. The patient's motivation was purely cosmetic because the eye was blind.

To resolve her problem, we moulded her right eye and fitted it with a minimum clearance scleral cosmetic contact lens painted to match her sighted eye. Following this, we fitted a monocular ptosis crutch in the usual manner. One problem did cause some concern because the ptosis crutch rested upon the cosmetic contact lens and moved it inferiorly. After several attempts, the crutch and lens were brought into proper balance with the result shown in color plate 11.

The patient also reported that after three months of usage she could elevate her lid to a moderate degree when not using the crutch. She also expressed a remarkable improvement in her emotional state and her own self image. Her marked change in appearance, dress, and cheerful demeanor upon visiting our office, bore witness to her report. She now travels alone to our office from a distance of 100 miles, which she would never attempt before, and for the first time since her accident, she dines in the employees' cafeteria at her place of work, where she draws no comments regarding her eyes.

These three patients represent a good cross section of the type of blepharoptosis patients that can be helped immeasurably by a palpebral prosthesis. However, there is one other type worth mentioning.

## Correction of partial ptosis

A partial ptosis is not cosmetically troublesome, but it causes a reduction in vision by cutting across the middle of the pupil.

One patient, female, age 60, presented a complaint that her vision was unsatisfactory unless she physically lifted her lids. Her vision without this lift was a fair 20/30 in each eye. Upon physically lifting her lids, she went to a good 20/15 and expressed a marked improvement in the brightness of objects. Reluctantly, we fitted her with a bilateral crutch, and to our surprise and her great satisfaction, she wears them almost all of her waking hours.

A similar patient, female, age 70 plus, came to us with a corrected acuity of O.D. 20/40, O.S. 20/50, with a partial monocular ptosis of her left eye. Her right eye showed early senile macular degeneration, but her left eye was normal. She stated in her history, that she watched a great deal of television, but had to hold her left lid up to enjoy it and in so doing, her left arm became very weary. Physically lifting her left lid improved her acuity to 20/25, with an accompanying increase in brightness and intensity. A monocular prosthesis gave the same results and physically lifting her lid was no longer necessary.

## Correction of blepharospasm

The correction of blepharoptosis is relatively simple compared to the relief of blepharospasm and I must confess to limited experience. However, while quite uncommon, the relief of blepharospasm was reported in the literature by Dr. J. C. Neill, in 1932.<sup>5</sup>

The first patient, female, age 63, presented a bilateral blepharospasm, moderate on her right side and severe on her left. She could control her lids for short intervals,



but the frequency of her spasms created a severe handicap for normal daily function. She also had multiple sclerosis of long standing and her neurologist believed this to be a contributing factor. She had several surgical interventions by Dr. Arthur Battista, a neurologist at New York University Hospital, who has considerable experience in performing a procedure referred to as "percutaneous fractional thermolysis of branches of facial nerve."<sup>6</sup> There was substantial improvement, although not complete. At times, she would experience an increase in the spastic activity. Our purpose was to prescribe a ptosis crutch to augment the beneficial effects of the blepharospasm surgery. By use of a heavier wire of 0.028 inch thickness, we were successful in alleviating the spasms for a period of four to six hours at a time, until the patient found the prosthesis intolerable. During the trial periods, we also tried a thinner wire of 0.020 gauge, for her left eye, with the temporal edge fixed to provide increased strength with some flexibility. The problem with a fixed prosthesis is the interference with lid closure and forward displacement of the spectacles through the force of the upper lid action. We now exclusively use prostheses with a free temporal end and vary the gauge of the wire to produce optimum lid action.

A second patient, male, age 65 presented a severe bilateral blepharospasm, more extreme on his right eye. The spasm was so frequent that the patient had difficulty functioning and exhibited a great fear of walking. His blepharospasm was so severe that he could not open his eyes and had to stand immobilized until the spasm was alleviated. During the spasm, his entire face was contorted with lid completely shut and his teeth were tightly clenched (color plate 12). In view of the extreme force generated during the spasm, we utilized a

0.032 gauge wire and adjusted it for the proper position. The spectacle frame had riding bow temples which helped, but we had to resort to using a head band as well, to counteract the force of the blepharospasm.

After several attempts which required changes in frame and bridge design and varying the gauge of the wire, we obtained a reasonably satisfactory result which permits the patient to wear the crutch at four hour intervals. Color plate 13 demonstrates partial relief of the spasm and a lid aperture of 2 mm in his right eye and 3 mm in his left. This is more than enough to permit him to walk and function normally.

We recommended to the referring optometrist that the patient should consider the thermolytic destruction of the facial nerves to the eyelids, as performed on the previous patient. If this is successful, the combination of surgery and prosthetic device may prove beneficial in this case.

### Summary

In conclusion, this paper attempted to demonstrate an improved design of a prosthetic device for ptosis and blepharospasm, utilizing orthodontic wire of spring tempered quality and of various gauges. Proper placement, form, use of the proper gauge material, and correct spectacle frame selection are essential for the success of this prosthesis. This device has greatly enhanced the functional aspects of ptosis crutches, by permitting adequate elevation and complete closure of the lid, to prevent drying of the cornea. A secondary advantage is cosmetic, because it permits use of modern plastic frames and tends to hide the crutch more readily.

While these cases are quite dramatic, it is obvious that ptosis presents a serious emotional, as well as visual problem and every non-surgical means should be explored

to correct the condition, before surgery is resorted to. The use of this new material and the proper placement and design of this crutch can correct many types of ptosis. The cosmetic improvement is startling, the emotional impact is rewarding and the possibility of prolonged functional improvement mandates the use of a ptosis crutch in all cases where medical treatment fails or is contra-indicated.

As far as blepharospasm is concerned, the results are at best, equivocal. Two patients are insufficient to draw any conclusion, except to say that there is some possibility of relief. Surgical intervention may still be the treatment of choice and a prosthesis may be utilized to stabilize or enhance the results of the surgery. More time and experience in the surgical area and design of a prosthetic device may lead to a better result in a very difficult, resistant anomaly. **AOA**  
Submitted for publication 10/81.

115 Main St.

Woodbridge, NJ, 07095

### FOOTNOTE

- a. #304 stainless steel wire and teflon tubing are available from local orthodontists, orthodontic laboratories or suppliers, in most major cities.

### REFERENCES

1. Neill JC: Ptosis crutches and facial masks. *Report of the Transactions of the 10th Annual Meeting, American Academy of Optometry, 1931*. Minneapolis: American Journal of Optometry, 1932, pp 94-107.
2. Allen JH (ed): *May's Manual of the Diseases of the Eye*, ed 24. Baltimore: Williams & Wilkins, 1968, p 55.
3. Wood CA (ed): *The American Encyclopedia and Dictionary of Ophthalmology*. Vol 14. Chicago: Cleveland Press, 1919, pp 10471-10472.
4. Tillisch AE: Comments on the use of the ptosis crutch. *Am J Optom Arch Am Acad Optom* 31(3):137-139, Mar 1954.
5. Neill JC (1932)
6. Battista AF: Hemifacial spasm and blepharospasm: Percutaneous fractional thermolysis of branches of facial nerve. *NY State J Med* 77(14):2234-2237, Dec 1977.